



Andrological Potential of Aqueous Leaf Extract of *Stevia rebaudiana* in Male Wistar Rats

George O. Eidangbe^{a*}

^a *Department of Medical Biochemistry, College of Medicine, Ambrose Alli University, Ekpoma, Edo State, Nigeria.*

Author's contribution

The sole author designed, analyzed, interpreted and prepared the manuscript.

Article Information

DOI: <https://doi.org/10.9734/jocamr/2024/v25i12601>

Open Peer Review History:

This journal follows the Advanced Open Peer Review policy. Identity of the Reviewers, Editor(s) and additional Reviewers, peer review comments, different versions of the manuscript, comments of the editors, etc are available here: <https://www.sdiarticle5.com/review-history/127206>

Original Research Article

Received: 03/10/2024

Accepted: 05/12/2024

Published: 16/12/2024

ABSTRACT

This study aimed to investigate the effects of an aqueous leaf extract of *Stevia rebaudiana* (Bertoni) on male Wistar rats administered alloxan. Thirty (30) male Wistar rats, comprising six normoglycemic (NC) and twenty-four (24) alloxan-induced diabetic (D) specimens. The diabetic rats were divided into four groups (n = 6): DC, diabetic rats receiving distilled water; DGL, diabetic rats receiving glibenclamide; DSR100, diabetic rats receiving 100 mg/kg bw *S. rebaudiana*; and DSR200, diabetic rats receiving 200 mg/kg bw *S. rebaudiana*. Treatment was administered daily via gavage for a duration of 15 days. At the conclusion of the treatment session, the animals were subjected to overnight fasting prior to being euthanized via cervical dislocation, following which blood was collected for serum extraction. Body weight, fasting blood glucose (FBG) levels, serum malondialdehyde (MDA) levels, and total antioxidant capacity (TAC) were evaluated. Furthermore, sperm parameters, serum follicle-stimulating hormone (FSH), luteinizing hormone (LH), and

*Corresponding author: E-mail: olubamichael2023@gmail.com;

testosterone levels were assessed. The data indicated a significant ($P = .05$) reduction in body weight in the DC group compared to the NC group. Significant ($P = .05$) enhancement in body weight was observed in DSR100 and DSR200 relative to DC. Significant ($P = .05$) elevations in serum FBG and MDA, accompanied by equivalent reductions in TAC, were noted in DC relative to NC. The total abnormal sperm count and percentage of sperm abnormalities were significantly ($P = .05$) elevated in DC compared to NC. Nonetheless, FBG, MAD, total abnormal sperm count, and percentage of sperm abnormalities exhibited significant ($P = .05$) reduction in the DSR100 and DSR200 groups compared to the DC group. The findings of this investigation substantiate the assertion that *S. rebaudiana* exhibits andrological action in rats.

Keywords: *Stevia rebaudiana*; diabetes; male infertility; andrological; Wistar rats.

1. INTRODUCTION

Diabetes mellitus is a chronic metabolic disorder characterized by high glucose levels (hyperglycemia) resulting from insufficient insulin production and/or insulin resistance (Zhao et al., 2023). The disorder results from a diminished capacity to metabolize carbohydrates caused by changes in insulin function (Giri et al., 2018). This ancient sickness affecting humans is progressively worsening and nearing pandemic levels. The worldwide incidence of the disease is swiftly increasing, with projections indicating that 366 million individuals are expected to have diabetes by 2030, in contrast to the 191 million forecast in 2000 (Gregory et al., 2022).

In developing countries, medicinal plants remain the principal therapeutic option for diabetes owing to the high cost of diabetic drugs and their related side effects. Worldwide, individuals have employed several therapeutic herbs, including *Stevia rebaudiana*, for diabetes treatment (Chowdhury et al., 2022). It is crucial to evaluate the antidiabetic qualities and other physiological impacts of these plants to establish scientific proof and confirm their application in ethnomedicine.

Stevia rebaudiana (Bertoni), a member of the Asteraceae family, is indigenous to northern South America (Chowdhury et al., 2022). It is found in numerous places of Brazil, Paraguay, Central America, Thailand, and China. Stevia, recognized as a calorie-free sugar alternative, is extensively utilized for its natural sweetness. Steviol glycoside, the primary sweetening agent, is around 200–300 times sweeter than sucrose, rendering it a prevalent alternative for managing caloric intake and enhancing metabolic health. Recent study suggests that, beyond its sweetening properties, stevia may offer several pharmacological benefits, including the potential to decrease blood sugar levels, lessen

hypertension, and mitigate inflammation (Munir et al., 2024). This study indicates that specific components in stevia may affect hormone levels, particularly by modulating androgenic activity (Elshafey et al., 2023; Saedi et al., 2024). Androgens, such as testosterone, significantly affect male physiology by regulating reproductive function, muscle mass, and general well-being (Ide, 2023). Understanding the potential anti-androgenic benefits of stevia is essential, especially given its increasing global consumption. The present study sought to evaluate the possible andrological effects of providing an aqueous leaf extract of *S. rebaudiana* to male Wistar rats.

2. MATERIALS AND METHODS

2.1 Materials

2.1.1 Plant material

Fresh leaves of *S. rebaudiana* were harvested from a young plant in an agro-forestry area of Ipele, Ondo State (Nigeria). A Taxonomist at the Department of Plant Biology, University of Ilorin, Ilorin, Nigeria, identified and authenticated the leaf.

After cleaning, the Stevia leaves were air-dried in the shade at ambient temperature and meticulously powdered using a kitchen blender. The powdered sample was extracted with distilled water and maintained in the laboratory for 72 h in a percolator and filtered using Whatman filter sheets. The extract was further purified and evaporated in a water bath for 72 h. The extract was then weighed and subsequently diluted with distilled water. Prior to delivery, all extracts were filtered using 0.22- μm pore syringe filters (Ganjani et al., 2020).

2.1.2 Experimental animals

Thirty adult male Wistar rats, with an average weight ranging from 120.5 to 150.0 g, were

sourced from Ibadan and housed at the Experimental Animal House, Department of Biochemistry, Landmark University, Omu-Aran, Nigeria. The subjects were maintained in stainless steel cages featuring wired floors, under a 12-hour light/dark cycle, with humidity levels ranging from 25% to 35% and a temperature of 20 to 22 °C. They were provided with commercially pelletized rat chow and had ad libitum access to clean water. The research was carried out in compliance with the guidelines set forth by the Animal Care Use and Research Ethics Committee at Landmark University, Omu-Aran, Nigeria, receiving approval under LUAC/BCH/2023/0004.

2.2 Methods

2.2.1 Animal treatment

The rats were allocated randomly into five groups (n = 6). Group 1 (control) included normoglycaemic rats that were administered 1 mL of normal saline via gavage. Groups 2 to 5 comprised alloxan-induced diabetic rats, which were rendered diabetic through a single intraperitoneal injection of 100 mg/kg alloxan monohydrate (Sigma-Aldrich). Group 2 comprised diabetic rats receiving distilled water, group 3 included diabetic rats treated with 0.07 mg/kg glibenclamide, while groups 4 and 5 consisted of diabetic rats administered 100 mg/kg and 200 mg/kg of *S. rebaudiana*, respectively. Treatment was administered daily via gavage.

2.2.2 Animal sacrifice and sample collection

After treatment for 15 days, the animals were weighed individually before being anesthetized with a mixture of ketamine (80 mg/kg) and xylazine (5 mg/kg), followed by sacrifice via cervical dislocation. Five milliliters (5 mL) of blood were obtained from each animal via cardiac puncture. The testicles were excised and weighed, and the epididymides were extracted for sperm analysis and stereological examination.

2.2.3 Sample preparation

Following a 20-minute coagulation period at ambient temperature, the blood samples were transferred to centrifuge tubes and subjected to centrifugation for 15 min at 3000 rpm, resulting in the separation of their serum.

2.2.4 Sperm parameters assessment

Orchidectomy was performed via a prescrotal or midline incision, following the method of Oridupa et al. (2017). The tunica vaginalis was removed to reveal the testicles, which were extracted from the incision site. The spermatic cord was ligated and excised, and sperm samples were obtained from the caudal epididymis. Sperm morphology was assessed from around 400 spermatozoa in stained smears (Ham's F10 medium; 1 ml, 30 min). Spermatozoa were enumerated utilizing a Neubauer hemocytometer slide. A 10 µL aliquot of sperm suspension was deposited on the Neubauer slide, and sperm concentration was determined in five squares using a light microscope at ×40 magnification. A 10-µL specimen was utilized on a preheated Neubauer slide with a coverslip for sperm motility evaluation. A minimum of five microscopic fields (×40 magnification) were meticulously examined to characterize 200 spermatozoa. Motility was quantified as a percentage of progressive (both rapid and slow), nonprogressive, and immotile spermatozoa. A Diff-Quik™ staining set was utilized to assess sperm morphology. Normal sperm are anticipated to lack malformations in the head, neck, and tail, but defective sperm may exhibit one or more of these anomalies (Abdollahi et al., 2022). A minimum of 200 spermatozoa from each mouse were analyzed to assess sperm motility, normal morphology, and sperm count.

2.2.5 Biochemical analyses

The fasting blood glucose level was measured using blood from the tail vein of each animal, utilizing a glucometer (Accu-Chek® Active, Roche Diagnostic, Germany). Serum levels of follicle-stimulating hormone (FSH), luteinizing hormone (LH), and testosterone (ng/ml) were evaluated using specific ELISA kits for rats (Bioassay Technology Laboratory, China).

2.3 Statistical Analysis

Results are presented as means ± SEM of six independent determinations. Statistical analysis was performed using one-way analysis of variance (ANOVA). Mean comparison was by Duncan Multiple Range Test. The mean concentrations were tested for significant difference at the 95% confidence level, a P-value of <0.05 was considered significant.

3. RESULTS AND DISCUSSION

This study aimed to assess the impact of aqueous leaf extract of *S. Rebaudiana* on diabetic problems associated with male infertility in diabetic rats. Animal weight was significantly ($P = .05$) reduced following alloxan administration (Fig. 1a). Administration of *S. rebaudiana* at doses of 100 and 200 mg/kg bw. enhances body weight in alloxan-induced diabetic rats. An elevation in the extract dosage exerted no substantial impact on body weight. The extract's impact on the rats' body weight was comparable to that of glibenclamide (a standard anti-diabetic medication) but significantly ($P = .05$) lower than that observed in normoglycemic rats (Fig. 1 a). Prior research by Oluba et al. (2019) has indicated the detrimental effect on the body weight of rats resulting from alloxan induction, consistent with the findings of this investigation. The decrease in body weight in diabetic rats can be ascribed to the anticipated deficiency in cellular energy intake resulting from impaired glucose uptake, which prompts the catabolism of cellular lipid and protein reserves as an alternative energy source.

At the conclusion of the treatment period, fasting blood glucose levels were significantly ($P = .05$) elevated in the diabetic control (DC) rats relative to the normoglycemic control (NC) group. Glibenclamide normalized fasting blood glucose levels, while *S. rebaudiana*-treated rats exhibited a significantly ($P = .05$), dose-dependent reduction compared to the diabetic control, although their levels remained significantly higher than the normal control (Fig. 1b).

In agreement with previous report, our findings indicated that elevated blood fasting blood glucose levels were associated with alloxan-induced diabetes in rats due to the rapid destruction of beta cells (Karganov et al., 2020). The reduction in fasting blood glucose concentration due to aqueous leaf extract of *S. rebaudiana* in diabetic rats in this study is in agreement with reports from earlier studies (Bayat et al., 2020; Hussain & Hafeez, 2021). Prior research has shown that *S. rebaudiana* revitalizes beta cells, hence restoring the glycogen synthase system through increased insulin synthesis and hepatic glycogen storage, which mediates its impact on blood glucose homeostasis (Elshafey et al., 2023; Abdi et al., 2023).

Fig. 1c indicates that serum malondialdehyde (MDA) levels were significantly ($P = .05$) elevated in alloxan-induced diabetic (DC) rats compared to normoglycemic (NC) rats. The administration of aqueous leaf extract of *S. rebaudiana* resulted in a dose-dependent decrease in blood MDA levels in alloxan-induced diabetic rats after 15 days of oral treatment. Elevated serum MDA concentration in alloxan-induced diabetes in rats has been reported by several authors (Oluba et al., 2019). MDA serves as a crucial marker of oxidative stress, arising from an overloaded cellular antioxidant system. The production of reactive oxygen species resulting from secondary glucose pathways, an adaptive mechanism in diabetes, induces oxidative stress.

The serum total antioxidant capacity (TAC) exhibited an inverse connection with serum malondialdehyde (MDA) content. Consequently, the TAC in DC rats was significantly ($P = .05$) decreased in comparison to NC. A notable enhancement in serum total antioxidant capacity (TAC) was seen in alloxan-induced diabetic rats administered with aqueous leaf extract of *S. rebaudiana* (Fig. 1d) in comparison to the diabetic control (DC). Studies have associated elevated levels of oxidant species with male infertility (Takeshima et al., 2021). Research has indicated that oxidative stress is involved in approximately 30–80% of male infertility cases (Takeshima et al., 2021). Oxidative stress adversely affects the reproductive system and sperm, leading to diminished sperm motility, lipid peroxidation, impaired oocyte-sperm fusion, and heightened DNA damage (Vahedi Raad et al., 2024). Numerous studies have demonstrated that reactive oxygen species significantly influence spermatogenesis and sperm functionality. Excessive generation of reactive oxygen species was found to adversely affect sperm motility, morphology, and concentration, while also inducing DNA damage and apoptosis (Vahedi Raad et al., 2024). This study showed that the treatment of aqueous leaf extract of *S. rebaudiana* reduced serum MDA levels and enhanced serum total antioxidant capacity in rats with alloxan-induced diabetes. This discovery aligns with findings from prior investigations. Stevioside is a flavonoid present in *S. rebaudiana* leaves that may reduce blood sugar levels and combat free radicals (Elhassaneen et al., 2022; Elsemelawy et al., 2021). Research has shown that flavonoids reduce the levels of free radicals, therefore alleviating the difficulties related to diabetes.

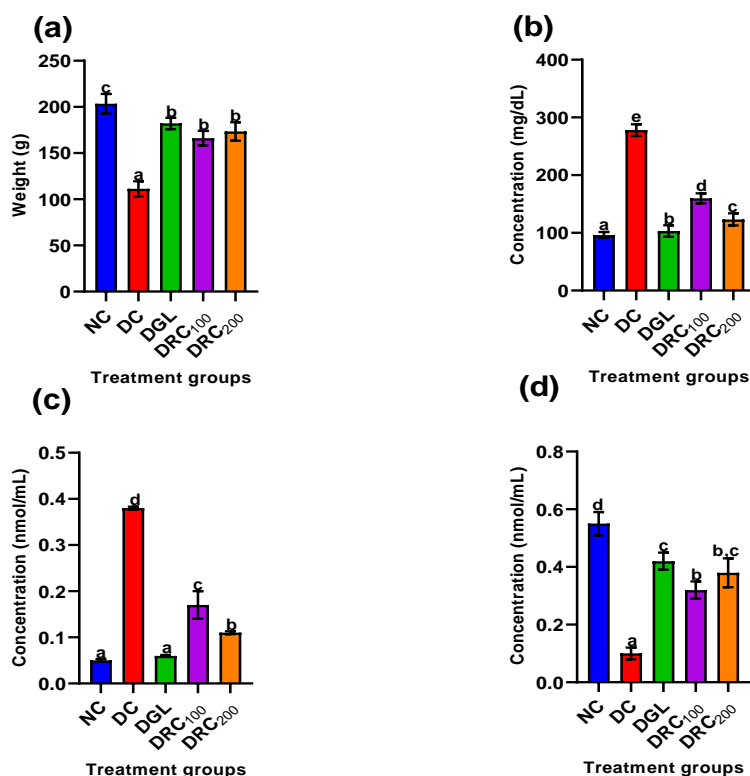


Fig. 1. (a) Body weight, serum concentrations of (b) fasting blood glucose, (c) malondialdehyde, and (d) total antioxidant capacity in alloxan-induced male diabetic Wistar rats administered aqueous leaf extract of *S. rebaudiana* for 15 days. Data are means \pm SEM of six determinations. Bars carrying different alphabets are statistically significant ($p < 0.05$).

Note: NC, normoglycemic rats; DC, alloxan-induced diabetic rats; DGL, alloxan-induced diabetic rats treated with glibenclamide; DSR₁₀₀, alloxan-induced diabetic rats administered 100 mg/kg of aqueous leaf extract of *S. rebaudiana*; and DSR₂₀₀, alloxan-induced diabetic rats administered 200 mg/kg of aqueous leaf extract of *S. rebaudiana*.

The prevalence of primary abnormalities, such as rudimentary tails, and secondary sperm abnormalities, including normal heads without tails, normal tails without heads, bent tails, curved tails, and looped tails, was significantly elevated in the diabetic control rats compared to the normoglycaemic rats (NC) and the diabetic treated groups (DGL, DSR₁₀₀, and DSR₂₀₀). While the overall sperm count did not exhibit statistical differences across the groups, the total count of aberrant sperm was considerably ($p < 0.05$) elevated in the DC group compared to the NC and diabetic-treated groups. The percentage of sperm abnormalities was significantly ($P = .05$) higher in the DC group compared to the NC and diabetic-treated groups. Sperm motility and volume were significantly ($P = .05$) reduced in the DC group compared to the NC and diabetic-treated groups (Table 1). One of the major diabetic complications in males include infertility and erectile disorders. Male infertility may be due

to defects in spermatozoa morphology and characteristics (Moretti et al., 2022). As earlier mentioned, the augmentation of lipid peroxidative in diabetes has a negative consequence on sperm production and function. Excessive production of reactive oxidant species harmed sperm motility, morphology, and concentration. In the present study, treatment with aqueous leaf extract of *S. rebaudiana* was observed to reverse the derangements in sperm morphology and characteristics associated with alloxan-induced diabetes in rats. This is indicative of the spermatogenic and andrological potentials of the extract (Abdi et al., 2023). The antioxidant activity of aqueous leaf extract of *S. rebaudiana* in the form of reduced MDA level and enhanced antioxidant capacity in alloxan-induced diabetic male Wistar rats as reported in this study may be beneficial in enhancing spermatogenesis and sperm function.

Table 1. Spermatozoa abnormalities

	NC	DC	DG	DSR ₁₀₀	DSR ₂₀₀
Rudimentary tail	3.3 ± 0.3 ^a	4.5 ± 0.2 ^b	3.0 ± 0.3 ^a	3.4 ± 0.2 ^a	3.3 ± 0.3 ^a
Normal head without tail	4.0 ± 0.3 ^a	6.9 ± 0.3 ^b	4.1 ± 0.1 ^a	4.2 ± 0.3 ^a	4.1 ± 0.2 ^a
Normal tail without head	4.1 ± 0.2 ^a	6.5 ± 0.5 ^b	4.1 ± 0.5 ^a	4.2 ± 0.2 ^a	4.3 ± 0.3 ^a
Bent tail	10.3 ± 0.3 ^a	12.1 ± 0.5 ^b	10.3 ± 0.3 ^a	10.4 ± 0.5 ^a	10.4 ± 0.3 ^a
Curved tail	10.1 ± 0.4 ^a	11.8 ± 0.5 ^b	10.0 ± 0.3 ^a	10.2 ± 0.5 ^a	10.2 ± 0.7 ^a
Curved mid-piece	10.3 ± 0.3 ^a	10.5 ± 0.3 ^a	10.3 ± 0.5 ^a	10.4 ± 0.3 ^a	10.4 ± 0.3 ^a
Bent mid-piece	9.9 ± 0.2 ^a	10.2 ± 0.4 ^a	9.9 ± 0.3 ^a	10.1 ± 0.3 ^a	10.0 ± 0.2 ^a
Looped tail	2.5 ± 0.2 ^a	3.8 ± 0.3 ^b	2.5 ± 0.2 ^a	2.6 ± 0.2 ^a	2.6 ± 0.1 ^a
Total abnormal sperm count	54.5 ^a	66.3 ^b	54.2 ^a	55.5 ^a	55.3 ^a
Total sperm count	415.8 ± 5.2 ^a	418.3±5.0 ^a	416.1±3.8 ^a	415.5±5.3 ^a	414.9±7.2 ^a
% Sperm abnormality	13.11 ^a	15.85 ^b	13.03 ^a	13.36 ^a	13.33 ^a
Sperm motility (%)	100	56.2	98.7	72.9	85.7

Data are means ± SEM of six determinations. Data in the same row carrying different alphabets are statistically significant at $P = .05$. Note: NC, normoglycemic rats; DC, alloxan-induced diabetic rats; DGL, alloxan-induced diabetic rats treated with glibenclamide; DSR₁₀₀, alloxan-induced diabetic rats administered 100 mg/kg of aqueous leaf extract of *S. rebaudiana*; and DSR₂₀₀, alloxan-induced diabetic rats administered 200 mg/kg of aqueous leaf extract of *S. rebaudiana*.

The serum follicle stimulating hormone (FSH) level was significantly ($P = .05$) decreased in alloxan-induced diabetic (DC) rats in comparison to normoglycemic rats (NC). After 15 days of treatment with aqueous leaf extract of *S. rebaudiana* (100 and 200 mg/kg bw), blood FSH levels were significantly ($P = .05$) elevated in comparison to the control group. The extract at 200 mg/kg body weight had an effect on serum FSH comparable to that of glibenclamide-treated rats (Fig. 2a). The serum levels of luteinizing hormone (LH) (Fig. 2b) and testosterone (Fig. 2c) exhibited a comparable pattern to that of follicle-stimulating hormone (FSH). Significant ($P = .05$) decreases in serum LH and testosterone levels were noted in DC rats relative to NC. After giving aqueous leaf extract of *S. rebaudiana* for 15 days, serum LH and testosterone levels were normalized, comparable to glibenclamide treatment.

This study revealed a negative association between androgen hormones (LH, FSH, and testosterone) and increased occurrences of sperm cell abnormalities in untreated alloxan-induced diabetic rats. This suggests disrupted spermatogenesis and sperm maturation, potentially resulting from low levels of these hormones and inadequate epididymal secretions (Singh et al., 2014). Kamaruzaman et al. (2018) indicated that *Gynura procumbens* significantly affected sperm maturation, contributing to the amelioration of diabetic male infertility through the upregulation of associated proteins. La Vignera et al. (2012) noted that diminished serum testosterone levels in diabetes correlate

with a steroidogenic impairment in Leydig cells and oxidative stress generated by hyperglycemia. Disruption in spermatogenesis and germ cell death was also noted in type 1 diabetes due to localized autoimmune injury. Additionally, compromised sperm parameters and diminished serum testosterone levels have been linked to type 2 diabetes as a result of insulin resistance, obesity, and other associated comorbidities (La Vignera et al., 2012; Kang et al., 2021). Consistent with prior research, administration of aqueous leaf extract from *S. rebaudiana* restored the depleted levels of testosterone, FSH, and LH in alloxan-induced diabetic in Wistar male rats (Abdi et al., 2023; Mekki et al., 2023). The use of medicinal plants such as *Teucrium polium*, *Eryngium caucasicum*, and *Zingiber officinalis* in reversing the decline in testosterone levels in a hypoglycemic state (Iranloye et al., 2011; Nouri et al., 2022). The inhibitory influence of *S. rubidianna* on serum MDA generation in a hyperglycemic condition may provide a potential mechanism for this effect (Abdi et al., 2023). The testes, owing to its highly vascularized nature, is particularly vulnerable to significant volumes of hyperglycemic blood, resulting in heightened exposure to reactive oxygen species, advanced glycation end products, and other toxicants (Singh et al., 2022). Moreover, diabetes-related impairment of Sertoli cells may contribute to the generation of abnormal spermatozoa, as Sertoli cells play a crucial role in spermatogenesis and sperm cell maturation (Minas et al., 2024). The observed reductions in serum follicle stimulating hormone (FSH), luteinizing hormone (LH) and testosterone

level in alloxan-induced diabetic rats in this study are in agreement with previous studies (Adebayo & Ajani, 2020; Osibemhe et al., 2023). Testosterone hormone secreted by the Leydig cell is pivotal in spermatogenesis as well as in the development of male secondary sexual characteristics (Zirkin and Papadopoulos, 2018). Previous research has shown that low serum testosterone levels in diabetic men lead to impaired spermatogenesis (Andlib et al., 2023). However, the observed increase in serum testosterone level in this study is in contrast with Gholizadeh *et al.* (Gholizadeh et al., 2019) that showed that *Stevia* administration did not affect low testosterone levels in STZ-induced diabetic rats. However, our report is in agreement with Ghaheri *et al.* (Ghaheri et al., 2018) who observed that prolonged administration of *Stevia* resulted in elevated testosterone levels in rats. It has been discovered that Leydig cells possess insulin receptors that have been related to testosterone production. Because of insufficient insulin synthesis, people with diabetes have experienced lower testosterone levels (Pitteloud et al., 2005). Moreover, it has been shown that reduced insulin levels have an adverse effect on Leydig cell activity by lowering blood LH levels, perhaps by a process involving FSH (Oduwole et al., 2021; Liu et al., 2021).

As has been reported by several authors, diabetes may have induced oxidative stress,

adversely affecting the male reproductive system, sperm morphology, sperm function, and DNA integrity (Minas et al., 2024; Laleethambika et al., 2019). Consistent with prior research, our results indicated that alloxan-induced diabetes adversely affected sperm count, motility, and morphology in rats (Njoku-Oji et al., 2019). Nonetheless, treatment with aqueous leaf extract of *Stevia* markedly enhanced these sperm parameters, consistent with other research (Gholizadeh et al., 2019). *Stevia* has demonstrated the ability to suppress the oxidative response in the testes of diabetic rats (Abdi et al., 2023; Gholizadeh et al., 2019). A recent study indicated that *S. rebaudiana* significantly enhanced antioxidant-related enzymes and spermatogenesis in rats with ischaemia/reperfusion injury (Abdi et al., 2023). Sperm generation is dependent on the proper functioning of Leydig and Sertoli cells, together with sufficient amounts of male sex hormones, which have been compromised by oxidative stress related to diabetes (Shah et al., 2021). As anticipated, *stevia*, owing to its antioxidant qualities, may enhance sperm parameters in alloxan-induced diabetic rats. Currently, our comprehension of how *Stevia* influences testosterone production remains in its nascent phases, necessitating further investigation before we can delineate a specific mechanism.

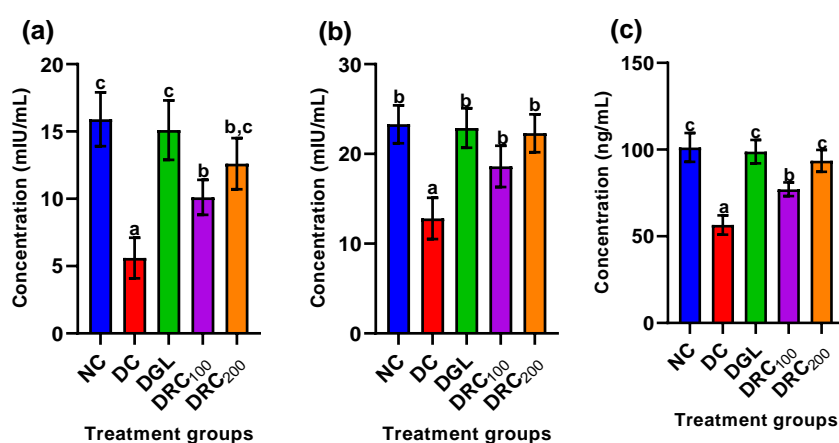


Fig. 2. Serum concentrations of (a) follicle-stimulating hormone (FSH), (b) luteinizing hormone (LH), and (c) testosterone in alloxan-induced male diabetic Wistar rats administered aqueous leaf extract of *S. rebaudiana* for 15 days. Data are means \pm SEM of six determinations. Bars carrying different alphabets are statistically significant ($p < 0.05$).

Note: NC, normoglycemic rats; DC, alloxan-induced diabetic rats; DGL, alloxan-induced diabetic rats treated with glibenclamide; DSR₁₀₀, alloxan-induced diabetic rats administered 100 mg/kg of aqueous leaf extract of *S. rebaudiana*; and DSR₂₀₀, alloxan-induced diabetic rats administered 200 mg/kg of aqueous leaf extract of *S. rebaudiana*

4. CONCLUSION

The most significant finding of this study is that the administration of *S. rebaudiana* aqueous leaf extract could optimally reduce diabetes-related complications leading to infertility in diabetic male rats. With the combination of these components, we observed an even more effective therapeutic potential for diabetes-related infertility, as evidenced by the following factors: lipid peroxidation inhibition, increased total antioxidant capacity, improved serum levels of sex hormones (FSH, LH, and testosterone), in addition to improvement in sperm movement, and other sperm parameters. Overall, data obtained in this study substantiate the assertion that *S. rebaudiana* exhibits andrological action in rats. Though this study presents some interesting findings on the andrological potential of aqueous leaf extract of *S. rebaudiana* especially in protecting against male-related infertility complications in alloxan-induced diabetes in male Wistar rats. However, further study is required to verify safety and effectiveness before clinical usage may be contemplated.

DISCLAIMER (ARTIFICIAL INTELLIGENCE)

Author(s) hereby declare that NO generative AI technologies such as Large Language Models (ChatGPT, COPILOT, etc) and text-to-image generators have been used during writing or editing of this manuscript.

CONSENT

It's not applicable.

ETHICAL APPROVAL

All authors hereby declare that "Principles of laboratory animal care" (NIH publication No. 85-23, revised 1985) were followed, as well as specific national laws where applicable. All experiments have been examined and approved by the appropriate ethics committee.

COMPETING INTERESTS

Author has declared that no competing interests exist.

REFERENCES

Abdi, M., Alizadeh, F., Daneshi, E., Abouzaripour, M., Fathi, F., & Rahimi, K.

(2023). Ameliorative effect of *Stevia rebaudiana* Bertoni on sperm parameters, in vitro fertilization, and early embryo development in a streptozotocin-induced mouse model of diabetes. *Zygote*, 31(5), 475-482.

<https://doi.org/10.1017/S0967199423000611>

Abdollahi, N., Nouri, M., Leilami, K., Mustafa, Y. F., & Shirani, M. (2022). The relationship between plant and animal based protein with semen parameters: A cross-sectional study in infertile men. *Clinical Nutrition ESPEN*, 49, 372-377.

<https://doi.org/10.1016/j.clnesp.2021.12.014>

Adebayo, A., & Ajani, E.O. (2020). Investigation of the effects of alloxan-induced diabetes on reproductive hormones (follicle stimulating, luteinizing, and prolactin), lipid profile and serum electrolytes in male and female Wistar rats. *African Journal of Science and Nature*, 7, 40-49.

Andlib, N., Sajad, M., Kumar, R., & Thakur, S.C. (2023). Abnormalities in sex hormones and sexual dysfunction in males with diabetes mellitus: A mechanistic insight. *Acta Histochemica*, 125(1), 151974.

<https://doi.org/10.1016/j.acthis.2022.151974>

Bayat, E., Rahpeima, Z., Dastghaib, S., Gholizadeh, F., Erfani, M., Asadikaram, G., & Mokarram, P. (2020). *Stevia rebaudiana* extract attenuates metabolic disorders in diabetic rats via modulation of glucose transport and antioxidant signaling pathways and aquaporin-2 expression in two extrahepatic tissues. *Journal of Food Biochemistry*, 44(8), e13252.

<https://doi.org/10.1111/jfbc.13252>

Chowdhury, A. I., Rahanur Alam, M., Raihan, M. M., Rahman, T., Islam, S., & Halima, O. (2022). Effect of stevia leaves (*Stevia rebaudiana* Bertoni) on diabetes: A systematic review and meta-analysis of preclinical studies. *Food Science & Nutrition*, 10(9), 2868-2878.

<https://doi.org/10.1002/fsn3.3049>

Elhassaneen, Y., El-Nabi, S. H., Mahran, M., Bayomi, A., & Badwy, E. (2022). Potential protective effects of strawberry (*Fragaria ananassa*) leaves against alloxan-induced type 2 diabetes in rats: Molecular, biological and biochemical studies. *Sumerianz Journal of Biotechnology*, 5(1), 1-5.

- Elsemelawy, S.A., Gharib, M.A., & Elhassaneen, Y.A. (2021). Reishi mushroom (*Ganoderma lucidum*) extract ameliorates hyperglycemia and liver/kidney functions in streptozotocin-induced type 2 diabetic rats. *Bulletin of the National Nutrition Institute of the Arab Republic of Egypt*, 57(1), 74-107.
- Elshafey, M., Erfan, O. S., Risha, E., Badawy, A. M., Ebrahim, H. A., El-Sherbiny, M., El-Shenbaby, I., Enan, E. T., Almadani, M. E., & Eldesoqui, M. (2023). Protective effect of *Stevia* on diabetic induced testicular damage: An immunohistochemical and ultrastructural study. *European Review for Medical & Pharmacological Sciences*, 27(22).
https://doi.org/10.26355/eurrev_202311_34390
- Ganjiani, V., Ahmadi, N., & Raayat Jahromi, A. (2020). Protective effects of *Stevia rebaudiana* aqueous extract on experimental unilateral testicular ischemia/reperfusion injury in rats. *Andrologia*, 52(2), e13469.
<https://doi.org/10.1111/and.13469>
- Ghaheeri, M., Miraghaee, S., Babaei, A., Mohammadi, B., Kahrizi, D., Haghghi, Z.M., & Bahrami, G. (2018). Effect of *Stevia rebaudiana* Bertoni extract on sexual dysfunction in streptozotocin-induced diabetic male rats. *Cellular and Molecular Biology*, 64(2), 6-10.
- Gholizadeh, F., Dastghaib, S., Koohpeyma, F., Bayat, E., & Mokarram, P. (2019). The protective effect of *Stevia rebaudiana* Bertoni on serum hormone levels, key steroidogenesis enzymes, and testicular damage in testes of diabetic rats. *Acta Histochemica*, 121(7), 833-840.
<https://doi.org/10.1016/j.acthis.2019.06.006>
- Giri, B., Dey, S., & Das, T. (2018). Sarkar, M., Banerjee, J., Dash, S. K. Chronic hyperglycemia mediated physiological alteration and metabolic distortion leads to organ dysfunction, infection, cancer progression and other pathophysiological consequences: An update on glucose toxicity. *Biomedicine & Pharmacotherapy*, 107, 306-328.
<https://doi.org/10.1016/j.biopha.2018.07.017>
- Gregory, G. A., Robinson, T. I., Linklater, S. E., Wang, F., Colagiuri, S., de Beaufort, C., Donaghue, K. C., Harding, J. L., Wander, P. L., Zhang, X., & Li, X. (2022). Global incidence, prevalence, and mortality of type 1 diabetes in 2021 with projection to 2040: A modelling study. *The Lancet Diabetes & Endocrinology*, 10(10), 741-760.
[https://doi.org/10.1016/S2213-8587\(22\)00181-2](https://doi.org/10.1016/S2213-8587(22)00181-2)
- Hussain, F., & Hafeez, J. (2021). Therapeutic attributes of *Stevia rebaudiana* leaves in diabetic animal model. *RADS Journal of Biological Research & Applied Sciences*, 12(1), 1-7.
- Ide, H. (2023). The impact of testosterone in men's health. *Endocrine Journal*, 70(7), 655-662.
<https://doi.org/10.1507/endocrj.EJ22-0737>
- Iranloye, B.O., Arikawe, A.P., Rotimi, G., & Sogbade, A.O. (2011). Anti-diabetic and anti-oxidant effects of *Zingiber officinale* on alloxan-induced and insulin-resistant diabetic male rats. *Nigerian Journal of Physiological Sciences*, 26(1).
- Kamaruzaman, K.A., Aizat, W.M., Mat, & Noor, M. (2018). *Gynura procumbens* improved fertility of diabetic rats: Preliminary study of sperm proteomic. *Evidence-Based Complementary and Alternative Medicine*, 2018, 9201539.
<https://doi.org/10.1155/2018/9201539>
- Kang, J., Choi, H.S., Choi, Y.H., Oh, J.S., Song, K., Suh, J., Kwon, A., Kim, H.S., & Chae, H.W. (2021). Testosterone levels in adolescents and young men with type 1 diabetes and their association with diabetic nephropathy. *Biology*, 10(7), 615.
<https://doi.org/10.3390/biology10070615>
- Karganov, M. Y., Alchinova, I. B., Tinkov, A. A., Medvedeva, Y. S., Lebedeva, M. A., Ajsuvakova, O. P., Polyakova, M. V., Skalnaya, M. G., Burtseva, T. I., Notova, S. V., & Khlebnikova, N. N. (2020). Streptozotocin (STZ)-induced diabetes affects tissue trace element content in rats in a dose-dependent manner. *Biological Trace Element Research*, 198, 567-574.
<https://doi.org/10.1007/s12011-020-02035-2>
- La Vignera, S., Condorelli, R.A., Vicari, E., D'agata, R., Salemi, M., & Calogero, A.E. (2012). High levels of lipid peroxidation in semen of diabetic patients. *Andrologia*, 44, 565-570. <https://doi.org/10.1111/j.1439-0272.2011.01261.x>
- Laleethambika, N., Anila, V., Manojkumar, C., Muruganandam, I., Giridharan, B., Ravimanickam, T., & Balachandar, V. (2019). Diabetes and sperm DNA damage: Efficacy of antioxidants. *SN*

- Comprehensive Clinical Medicine*, 1, 49-59. <https://doi.org/10.1007/s42399-019-00234-4>
- Liu, Z.J., Liu, Y.H., Huang, S.Y., & Zang, Z.J. (2021). Insights into the regulation on proliferation and differentiation of stem Leydig cells. *Stem Cell Reviews and Reports*, 1-3. <https://doi.org/10.1007/s12015-021-10171-7>
- Mekki, S., Belhocine, M., Bouzouina, M., Chaouad, B., & Mostari, A. (2023). Therapeutic effects of *Salvia balansae* on metabolic disorders and testicular dysfunction mediated by a high-fat diet in Wistar rats. *Mediterranean Journal of Nutrition and Metabolism*, 16(1), 21-39. <https://doi.org/10.1007/s12349-023-00421-4>
- Minas, A., Camargo, M., Alves, M.G., & Bertolla, R.P. (2024). Effects of diabetes-induced hyperglycemia on epigenetic modifications and DNA packaging and methylation during spermatogenesis: A narrative review. *Iranian Journal of Basic Medical Sciences*, 27(1), 3.
- Moretti, E., Signorini, C., Noto, D., Corsaro, R., & Collodel, G. (2022). The relevance of sperm morphology in male infertility. *Frontiers in Reproductive Health*, 4, 945351. <https://doi.org/10.3389/frhr.2022.945351>
- Munir, S., Hameed, S., Hussain, N., Khurshid, H., Hafeez, M., & Khan, L. A. (2024). Unveiling *Stevia rebaudiana*: Origins, composition, and health implications. *Food Science & Applied Microbiology Reports*, 3(1), 1-8. <https://doi.org/10.1016/j.fsamp.2023.100090>
- Njoku-Oji, N.N., Ifegwu, N.O., Umahi, G.O., Sobanke, A.O., & Uchefuna, R.C. (2019). Beneficial effects of ethanolic seed extract of *Cyperus esculentus* on blood glucose and sperm quality in alloxan-induced diabetic rats. *IOSR Journal of Pharmacy and Biological Sciences*, 14, 84-90.
- Nouri, A., Amini-Khoei, H., Rafiei,an-Kopaei, M., & Rahimi-Madiseh, M. (2022). Anti-diabetic and hepato-renal protective potential of hydroalcoholic extract of *Teucrium polium* in alloxan-induced diabetic rats. *Comparative Clinical Pathology*, 1-1. <https://doi.org/10.1007/s00580-022-03785-7>
- Oduwole, O.O., Huhtaniemi, I.T., & Misrahi, M. (2021). The roles of luteinizing hormone, follicle-stimulating hormone, and testosterone in spermatogenesis and folliculogenesis revisited. *International Journal of Molecular Sciences*, 22(23), 12735. <https://doi.org/10.3390/ijms222312735>
- Oluba, O. M., Adebisi, F. D., Dada, A. A., Ajayi, A. A., Adebisi, K. E., Josiah, S. J., & Odotuga, A. A. (2019). Effects of *Talinum triangulare* leaf flavonoid extract on streptozotocin-induced hyperglycemia and associated complications in rats. *Food Science & Nutrition*, 7(2), 385-394. <https://doi.org/10.1002/fsn3.1257>
- Oridupa, O. A., Folasire, O. F., Owolabi, A. J., & Aina, O. (2017). Effect of traditional treatment of diabetes mellitus with *Xanthosoma sagittifolium* on the male reproductive system of alloxan-induced diabetic Wistar rats. *Drug Research*, 67(6), 337-342. <https://doi.org/10.1055/s-0043-120588>
- Osibemhe, M., Orji, B., Omaji, G., Amune, E., & Ezekiel, J. (2023). Instability of alloxan-induced diabetes and its impact on sex and thyroid hormones in male Wistar rats: A pilot study. *Kuwait Journal of Science*, 50(1A).
- Pitteloud, N., Mootha, V.K., Dwyer, A.A., Hardin, M., Lee, H., Eriksson, K.F., Tripathy, D., Yialamas, M., Groop, L., Elahi, D., & Hayes, F.J. (2005). Relationship between testosterone levels, insulin sensitivity, and mitochondrial function in men. *Diabetes Care*, 28(7), 1636-1642. <https://doi.org/10.2337/diacare.28.7.1636>
- Saedi, A., Zarei, S., Vatanparast, M., Hajizadeh, M. R., Hosseiniara, R., Esmaili, O. S., Mohammad-Sadeghipour, M., Mirzaei, Z., & Mahmoodi, M. (2024). Therapeutic effects of stevia aqueous extract alone or in combination with metformin in induced polycystic ovary syndrome rats: Gene expression, hormonal balance, and metabolomics aspects. *Annales Pharmaceutiques Françaises*. Elsevier Masson.
- Shah, W., Khan, R., Shah, B., Khan, A., Dil, S., Liu, W., Wen, J., & Jiang, X. (2021). The molecular mechanism of sex hormones on Sertoli cell development and proliferation. *Frontiers in Endocrinology*, 12, 648141. <https://doi.org/10.3389/fendo.2021.648141>
- Singh, A., Kukreti, R., Saso, L., & Kukreti, S. (2022). Mechanistic insight into oxidative stress-triggered signaling pathways and type 2 diabetes. *Molecules*, 27(3), 950.

- <https://doi.org/10.3390/molecules27030950>
- Singh, A.K., Brar, P.S., & Cheema, R.S. (2014). Relationships among frozen-thawed semen fertility, physical parameters, certain routine sperm characteristics and testosterone in breeding Murrah buffalo (*Bubalus bubalis*) bulls. *Veterinary World*, 7(9), 644-651.
- Takeshima, T., Usui, K., Mori, K., Asai, T., Yasuda, K., Kuroda, S., & Yumura, Y. (2021). Oxidative stress and male infertility. *Reproductive Medicine and Biology*, 20(1), 41-52. <https://doi.org/10.1002/rmb2.12417>
- Vahedi Raad, M., Firouzabadi, A. M., Tofighi Niaki, M., Henkel, R., & Fesahat, F. (2024). The impact of mitochondrial impairments on sperm function and male fertility: A systematic review. *Reproductive Biology and Endocrinology*, 22(1), 83. <https://doi.org/10.1186/s12958-024-01143-6>
- Zhao, X., An, X., Yang, C., Sun, W., Ji, H., & Lian, F. (2023). The crucial role and mechanism of insulin resistance in metabolic disease. *Frontiers in Endocrinology*, 14, 1149239. <https://doi.org/10.3389/fendo.2023.1149239>
- Zirkin, B.R., & Papadopoulos, V. (2018). Leydig cells: Formation, function, and regulation. *Biology of Reproduction*, 99(1), 101-111. <https://doi.org/10.1093/biolre/iox187>

Disclaimer/Publisher's Note: The statements, opinions and data contained in all publications are solely those of the individual author(s) and contributor(s) and not of the publisher and/or the editor(s). This publisher and/or the editor(s) disclaim responsibility for any injury to people or property resulting from any ideas, methods, instructions or products referred to in the content.

© Copyright (2024): Author(s). The licensee is the journal publisher. This is an Open Access article distributed under the terms of the Creative Commons Attribution License (<http://creativecommons.org/licenses/by/4.0>), which permits unrestricted use, distribution, and reproduction in any medium, provided the original work is properly cited.

Peer-review history:
The peer review history for this paper can be accessed here:
<https://www.sdiarticle5.com/review-history/127206>