



# Insight in the Management of Traumatic Isolated Injury to Submandibular Gland: A Case Report

Joyce P. Sequeira <sup>a++</sup> and Akshit Batra <sup>a#\*</sup>

<sup>a</sup> Department of Oral and Maxillofacial Surgery, Yenepoya Dental College and Hospital, Mangalore, Karnataka-575018, India.

## Authors' contributions

This work was carried out in collaboration between both authors. Both authors read and approved the final manuscript.

## Article Information

DOI: <https://doi.org/10.9734/jpri/2025/v37i17643>

## Open Peer Review History:

This journal follows the Advanced Open Peer Review policy. Identity of the Reviewers, Editor(s) and additional Reviewers, peer review comments, different versions of the manuscript, comments of the editors, etc are available here: <https://www.sdiarticle5.com/review-history/128293>

Case Report

Received: 20/10/2024

Accepted: 23/12/2024

Published: 04/01/2025

## ABSTRACT

**Rationale:** Isolated submandibular gland injuries are infrequent and are mainly reported in the context of trauma.

**Patient Concerns:** A 32-year-old male patient presented to the ER with a history of self-fall following which there was a penetrating injury to the lower part of the right neck region.

**Diagnosis:** A diagnosis of soft tissue penetrating injury to the right submandibular gland was made, after a thorough patient history, vigilant clinical examination along with negative CT scan findings.

**Intervention:** A decision of wound debridement and exploration under local anesthesia was made, with layered closure being done. The postoperative period of the patient was managed with

<sup>++</sup> Professor and Ex-HOD;

<sup>#</sup> Post Graduate;

<sup>\*</sup>Corresponding author: E-mail: [batraa21@gmail.com](mailto:batraa21@gmail.com);

antibiotics, a course of oral glycopyrrolate, three times a day for 5 days, and pressure dressing to address the salivary leak.

**Outcomes:** The patient was followed up for one year without any evidence of recurrences.

**Take-away Lessons:** Presentation of isolated submandibular gland injury is unique but rare and should be diagnosed at the earliest to avoid any long-term complications.

*Keywords: Submandibular gland injury; penetrating injury; soft tissue trauma; isolated injury.*

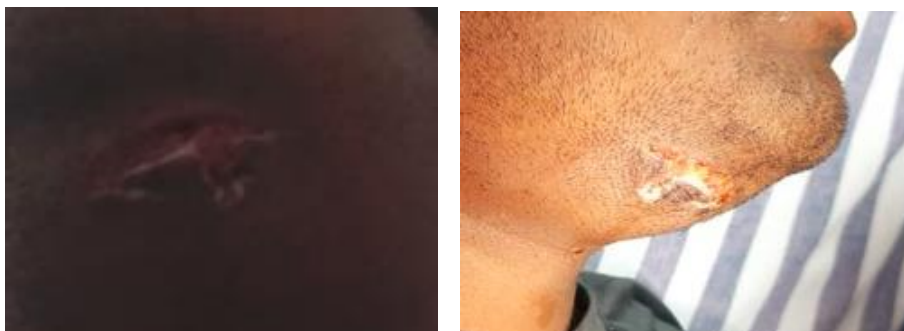
## 1. INTRODUCTION

“Humans are bestowed with excellent few major salivary glands and hundreds of minor salivary glands, located at a paramount anatomical location in the head and neck region” (Lazaridou et al., 2012). “Traumatic injury to the facial soft tissues and fractures of the maxillofacial complex might include the salivary structures, but the relative incidence of injury to these structures are surprisingly low. Salivary gland injuries are usually associated with penetrating injuries or complex fractures of the facial bones” (Liu et al., 2020). “These injuries can be serious and are frequently associated with long-term morbidity. Delay or failure to diagnose may result in morbidity secondary to soft tissue scarring and disfigurement, sialocele, cutaneous fistula, or gustatory sweating associated with Frey’s syndrome” (James et al., 2021). “Isolated submandibular gland injuries are sporadic and are mainly reported in the context of trauma” (Guntinas-Lichius, 2010). We, hereby report a rare case of isolated submandibular injury in the setting of penetrating injury from a fall, with emphasis on the evaluation, management, and review concerning traumatic submandibular injuries.

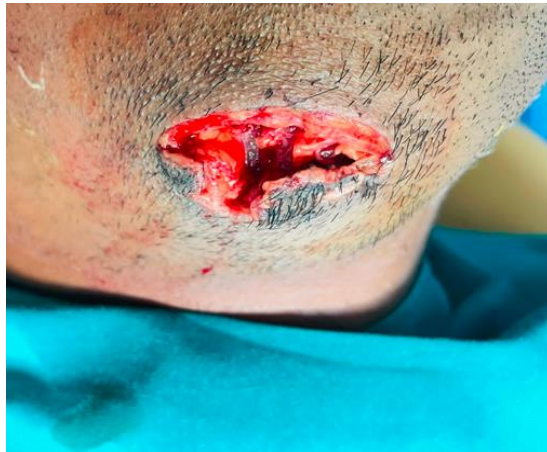## 2. CASE PRESENTATION

A young male patient in early thirties presented to the ER with a history of self-fall following which

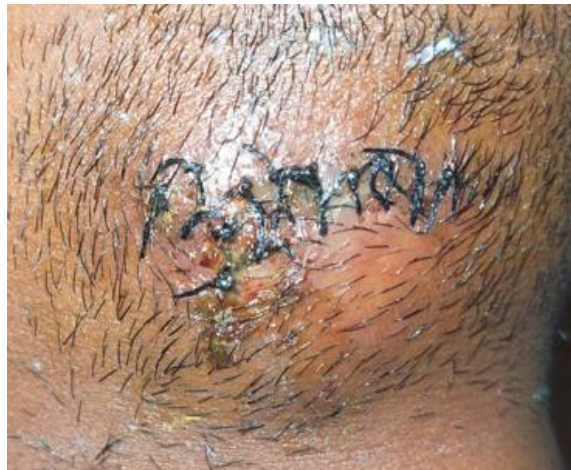there was a penetrating injury to the lower part of the right neck region. He had no loss of consciousness. Upon examination, a 3.5 cm x 0.5 cm laceration was noted with the right submandibular region, extra orally along with a 2 cm x 0.5 cm laceration noted with the right floor of the mouth region. The secondary survey did not reveal any associated injuries. Sensory and motor examination of the tongue was intact with preserved sensation at the right submandibular region and no deviation of the angle of the mouth. A constant, clear liquid was noticed to be dripping through the laceration. A diagnosis of soft tissue penetrating injury to the right submandibular gland was made, after a thorough patient history, vigilant clinical examination along with negative CT scan findings. A decision of wound debridement and exploration under local anesthesia was made, with layered closure being done. A tight intraoral suturing with close approximation and negative water holding test shed light and led to the confirmation of it being a salivary leak. Keeping in mind the same, the post-operative period of the patient was thus managed with antibiotics, a course of oral glycopyrrolate, 2mg, three times a day for 5 days, and a pressure dressing to address the salivary leak. Upon noting no complications and an uneventful post-operative period, the patient was discharged within one week, with suture removal being done on day 14. Subsequent follow-up periods reported no further complications.



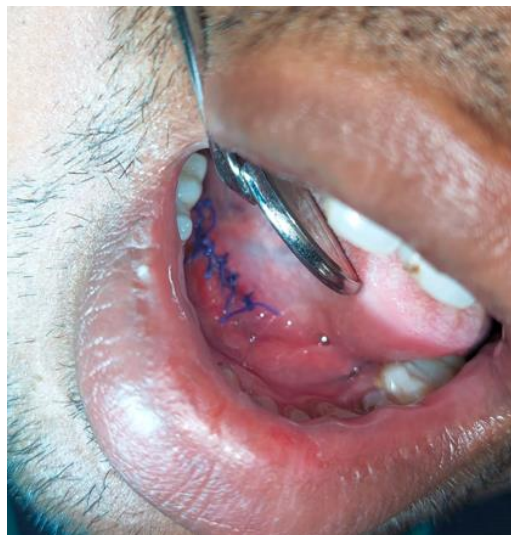**Fig. 1. A 3.5 cm x 0.5 cm laceration noted with the right submandibular region, extra orally secondary to the penetrating trauma**



**Fig. 2.** Upon dissection along the injured tissue, injury to the submandibular gland was noted with constant dripping throughout the procedure



**Fig. 3.** The extraoral wound was closed in layers with an absorbable Vicryl suture and a Non-resorbable Mersilk suture



**Fig. 4.** The intra-oral wound was closed using an absorbable Vicryl suture

### 3. DISCUSSION

Salivary gland trauma can be classified as acute (blunt, lacerating, avulsion, or blast injuries) or chronic (inflammatory damage associated with infection, foreign bodies, sialoliths, or irradiation). "Management of salivary gland injuries may vary according to factors such as the mechanism of injury, site of injury, degree of contamination, associated injuries, and the general medical status of the patient. Blunt trauma may result in the formation of a parenchymal contusion, hematoma, or laceration, and sometimes in the formation of a sialocele or a mucocele, whereas penetrating injuries may produce ductal lesions with a frequent incidence of a salivary fistula" (Lazaridou et al., 2012; Liu et al., 2020; James et al., 2021; Guntinas-Lichius, 2010).

"The submandibular gland lies below and in front of the angle of the mandible and occupies most of the posterior portion of the submandibular triangle (Callahan et al., 2022). Isolated submandibular gland injuries are sporadic because the gland is protected from the body of the mandible and are mainly reported in the context of trauma. Motor vehicle collisions are responsible for the majority of reported submandibular gland injuries, the mechanism being from airbag or seat belt-related injuries. Other forms of trauma include burns, stab, and gunshot wounds (James et al., 2021). Submandibular gland penetrating trauma to the floor of the mouth or beneath the mandible can damage the submandibular or sublingual glands. There are only a few case reports of isolated submandibular gland trauma in the literature" (Haller et al., 1999).

The diagnosis of salivary gland injury starts with increased suspicion of a potential injury based on the location and mechanism of trauma. The history and physical examination often provide useful information in the workup of possible salivary gland injury. Questions should be directed toward the presence of any suspicious swelling or drainage from the wound that might represent saliva, as well as the effects of food if the patient is taking an oral diet. When injuries are suspected with the submandibular gland, an assessment of tongue sensation and mobility may be helpful (Shupak et al., 2021). Radiographic imaging can be used to support the clinical suspicion of salivary gland and ductal injury, with a variable choice between magnetic resonance imaging (MRI), sialography with or without computed tomography (CT) imaging, or a CT scan alone. "Direct visualization of ductal

filling under fluoroscopy can be useful, particularly using digital subtraction techniques. Cannulation of the submandibular duct, especially in the trauma patient, may be difficult and its use with possible sublingual gland injury is not possible. If cannulation of the duct is unsuccessful, salivary gland function may be quantified by time-activity curves with <sup>99m</sup>Tc-pertechnetate scintigraphy and may distinguish between the functioning, obstructed, and nonfunctional glands. Ductal injuries can be demonstrated by MRI sialography, which is dependent on stimulated ductal salivary flow as the contrast medium, and correlates well with or even improves on conventional sialography" (Cochran et al., 2023).

"Glycopyrrolate is an anticholinergic medication, sometimes referred to as glycopyrronium. As a preoperative drug, glycopyrrolate is frequently used to suppress respiratory and salivary gland secretions. Anticholinergics are most commonly used to avoid reflex bradycardia, provide an antisialagogue action, and produce a sedative and amnesic effect. The main way that glycopyrrolate works is by inhibiting the effects of acetylcholine at the parasympathetic sites throughout different body parts. The central nervous system, smooth muscle, and secretory glands are the main sites of this obstruction. By inhibiting the acetylcholine receptors from being stimulated, it also lowers the rate of salivation. Glycopyrrolate does not pass through the placenta or the blood-brain barrier" (Harbison et al., 2010). Compared to other anticholinergic medications like atropine and scopolamine, it diffuses more slowly. One can administer glycopyrrolate intravenously, intramuscularly, orally, or topically. Injectable glycopyrrolate is supplied as a 0.2 mg/mL solution. There are three different strengths of oral tablets: 1 mg, 1.5 mg, and 2 mg, and one strength of oral solution is 1 mg/5 mL. The first dosage is 1 to 2 mg twice a day, and the patient's reaction to the treatment will determine how much is gradually increased. A single-use cloth pre-moistened with a 2.4% glycopyrronium solution is offered for the topical application. Both a dry powder inhaler (15.6 mcg capsule) and a nebulization solution (one 25 mcg vial breathed twice daily) are available for use in the inhalation formulation. Glycopyrronium inhibits sweating in the body. Consequently, in hot conditions, it may result in heat stroke and hyperthermia. Additional side effects that have been reported include constipation, diarrhea, headaches, dry mouth, and trouble urinating (Gallanosa et al.).

“Surgical and nonsurgical approaches, having their pros and cons are used in the treatment of salivary gland and ductal injuries. Nonsurgical approaches are generally used only when the gland parenchyma is contused but the ductal structures remain intact. Surgical techniques are used to repair extensive injuries. If trauma to the submandibular gland is identified during surgical exploration of the wound, removal of the gland is recommended as it is an easy procedure with a low complication rate. If trauma to the submandibular gland is not diagnosed during wound exploration, a submandibular fistula or a slowly expanding submandibular mass is likely to appear later, which demands a conservative treatment with antisialagogues, pressure bandages and aspiration which finally leads to fistula resolution (Alonso et al., 2022). If conservative measures prove unsuccessful, the surgeon should not hesitate to proceed to gland removal. Injuries to the duct of the submandibular gland should be treated with marsupialization of the gland in a more distal location to avoid an unnecessary stricture formation” (Shupak et al., 2021; Cochran et al., 2023; Alonso et al., 2022; Harbison et al., 2010).

Our case is unique in its own way as the presentation of the leak persisted extraorally even after a thorough intraoral suturing, with the water holding test being negative. All this ultimately paved to the confirmation of a salivary leak from the submandibular gland due to a penetrating injury. Glycopyrrolate oral administration and pressure dressing did wonders and led to the cessation of the leak.

#### 4. CONCLUSION

Unfortunately, injuries to the salivary glands and/or supporting structures are often overlooked or underestimated in patients who have suffered significant or massive facial trauma, with poor knowledge present especially concerning isolated submandibular gland injuries. A thorough assessment and proper management of these injuries can truly pave roads to preventing these economically high treatments with a positive outlook towards not tackling unpleasant late-term sequelae.

#### CONSENT AND ETHICAL APPROVAL

It is not applicable.

#### DISCLAIMER (ARTIFICIAL INTELLIGENCE)

Author(s) hereby declare that NO generative AI technologies such as Large Language Models (ChatGPT, COPILOT, etc) and text-to-image generators have been used during writing or editing of this manuscript.

#### COMPETING INTERESTS

Authors have declared that no competing interests exist.

#### REFERENCES

- Alonso, M. I., Barrios, L. A., Maya, J. L., Pérez, F. E., de Castro Almeida, A. R., & Pérez-Lara, A. (2022). Post-traumatic surgical emphysema and sialocele with fistula following knife wounds to the head and neck of a 30-year-old woman. *The American Journal of Case Reports*, 23, e934817-1. <https://doi.org/10.12659/AJCR.934817>
- Callahan, N., Licht, S., & Houle, A. (2022). Submandibular gland sialocele: A rare complication following open treatment of mandibular fracture. *Craniomaxillofacial Research & Innovation*, 7, 27528464221084175. <https://doi.org/10.1177/27528464221084175>
- Cochran, J., Gottfried, J., Chernichenko, N., Walvekar, R. R., & Butts, S. C. (2023). Traumatic injuries of the parotid gland and duct. *Otolaryngologic Clinics of North America*. <https://doi.org/10.1016/j.otc.2023.06.001>
- Gallanosa, A., Stevens, J. B., & Quick, J. (n.d.). Continuing education activity.
- Guntinas-Lichius, O. (2010). Trauma to the salivary glands and their management. In *Otorhinolaryngology, Head and Neck Surgery* (pp. 349-352). Springer Berlin Heidelberg. [https://doi.org/10.1007/978-3-540-77600-2\\_64](https://doi.org/10.1007/978-3-540-77600-2_64)
- Haller, J. R. (1999). Trauma to the salivary glands. *Otolaryngologic Clinics of North America*, 32(5), 907-918. [https://doi.org/10.1016/S0030-6665\(05\)70111-0](https://doi.org/10.1016/S0030-6665(05)70111-0)
- Harbison, J. M., & Page, M. P. (2010). Submandibular gland injury and delayed airway compromise caused by a seat belt. *American Journal of Otolaryngology*, 31(3), 209-211.

- <https://doi.org/10.1016/j.amjoto.2009.09.013>
- James, R., Soma, M., Leung, A., & Teo, S. S. (2021). Acute mandibular swelling following blunt trauma. *International Journal of Clinical Pediatrics*, 10(2-3), 43-48. <https://doi.org/10.24911/IJCP.10.2-3.43>
- Lazaridou, M., Iliopoulos, C., Antoniadis, K., Tilaveridis, I., Dimitrakopoulos, I., & Lazaridis, N. (2012). Salivary gland trauma: A review of diagnosis and treatment. *Craniomaxillofacial Trauma & Reconstruction*, 5(4), 189-195. <https://doi.org/10.1055/s-0032-1312153>
- Liu, C., Darian, A., Romeus, L., Cervantes, S., Westmoreland, T., & Cervantes, S. S. (2020). Submandibular gland injury with a ball bearing gunshot wound. *Cureus*, 12(10). <https://doi.org/10.7759/cureus.11088>
- Shupak, R. P., Williams, F. C., & Kim, R. Y. (2021). Management of salivary gland injury. *Oral and Maxillofacial Surgery Clinics*, 33(3), 343-350. <https://doi.org/10.1016/j.coms.2021.04.001>

**Disclaimer/Publisher's Note:** The statements, opinions and data contained in all publications are solely those of the individual author(s) and contributor(s) and not of the publisher and/or the editor(s). This publisher and/or the editor(s) disclaim responsibility for any injury to people or property resulting from any ideas, methods, instructions or products referred to in the content.

© Copyright (2025): Author(s). The licensee is the journal publisher. This is an Open Access article distributed under the terms of the Creative Commons Attribution License (<http://creativecommons.org/licenses/by/4.0>), which permits unrestricted use, distribution, and reproduction in any medium, provided the original work is properly cited.

*Peer-review history:*  
The peer review history for this paper can be accessed here:  
<https://www.sdiarticle5.com/review-history/128293>